



OUTBREAK OF JOINT INFECTIONS ASSOCIATED WITH MAGNETIC RESONANCE ARTHROGRAMS PERFORMED AT AN OUTPATIENT RADIOLOGY CENTER

Moon Kim, MD, MPH; Clara Tyson, BSN, PHN

INTRODUCTION

In 2009, the Los Angeles County (LAC) Department of Public Health's (DPH) Acute Communicable Disease Control Program (ACDC) was notified of a possible cluster of patients with joint infections after receiving magnetic resonance (MR) arthrograms at a single outpatient radiology center, Facility A. ACDC personnel spoke with the Chief Radiologist at Facility A and learned that at least two patients may have had joint infections with *Staphylococcus aureus* following MR arthrograms performed at Facility A both within one week period. ACDC conducted an investigation to confirm the presence of an outbreak, conduct case finding, determine the source of infection, and recommend control and prevention measures. An ACDC team consisting of a physician and public health nurse conducted a site visit and chart review to investigate whether there were other cases of joint infections following MR arthrograms performed at Facility A, reviewed infection control practices and the pharmaceuticals used during MR arthrograms. A second site visit was made by ACDC personnel to observe medication and contrast media preparation procedures for MR arthrograms.

ACDC consulted with the California Department of Public Health (CDPH) and the Centers for Disease Control and Prevention (CDC) Division of Healthcare Quality Promotion to discuss the methods and findings of this investigation and determine if other cases of joint infections following MR arthrogram procedures were reported in the state or nationally.

METHODS

A retrospective cohort study was conducted of patients who received MR arthrograms at Facility A to identify risk factors for joint infection. A confirmed case was defined as a patient who had an MR arthrogram procedure at Facility A, who developed signs and symptoms of joint infection with evidence of septic arthritis and microbiologic growth in the synovial fluid. A possible case was defined as a patient who had an MR arthrogram procedure at Facility A who had acute onset of new joint pain symptoms following the MR arthrogram procedure requiring further medical evaluation and had negative synovial fluid cultures. Case finding consisted of calling all patients who had received MR arthrograms during a two month period. Prospective surveillance was also performed by calling all patients who subsequently received MR arthrograms and inquiring about adverse events within one week following their procedure. Hospital inpatient and Facility A medical records of case-patients were reviewed. The chief radiologist and radiologic technologist (RT) staff were interviewed. Procedures for MR arthrograms were reviewed including infection control practices and pharmaceutical storage, preparation, and injection. An opened 10 mL single-dose vials of gadolinium contrast solution and an opened 100 mL single-dose vials of iodinated contrast solution were collected for testing by the public health laboratory.

RESULTS

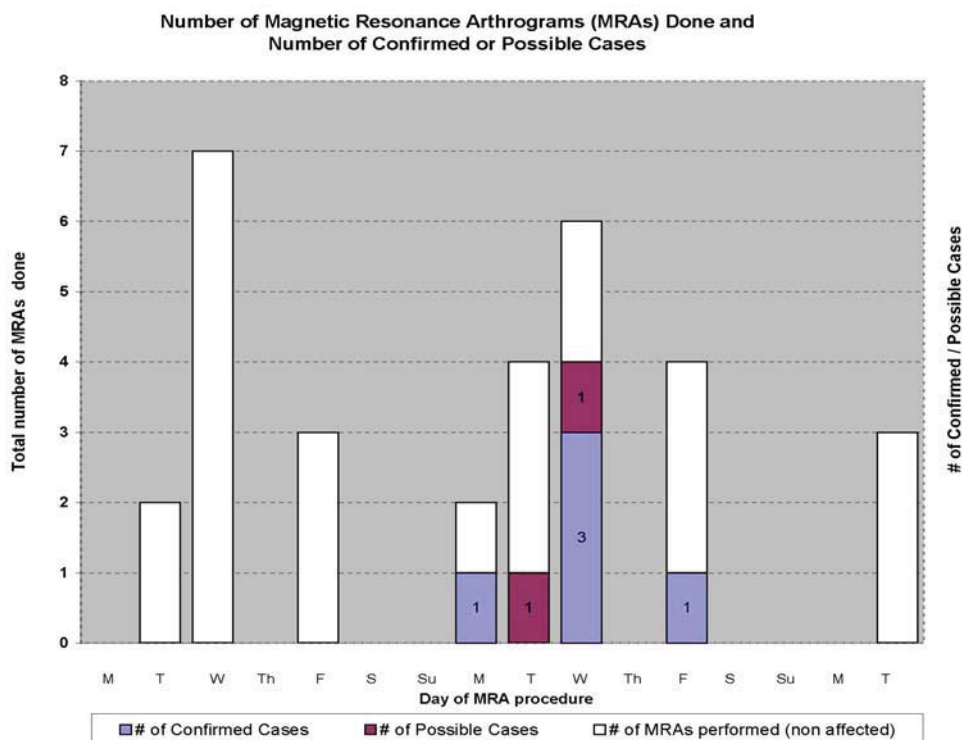
Medical Record review/Case Characterization

ACDC obtained a list of all patients who had MR arthrogram procedures at Facility A during the one week outbreak period. A total of 15 patients had this procedure done during this time period. ACDC contacted all 15 patients and/or their orthopedic surgeons by telephone. Medical records of those who were hospitalized or evaluated in an emergency department (ED) were reviewed. ACDC identified a total of seven case-patients (five confirmed, two possible) out of 16 MR arthrogram procedures performed on 15 patients (one patient had bilateral shoulder MR arthrograms) confirming the presence of an outbreak at Facility A (see Figure). Of the seven total case-patients, five presented initially to the ED or hospital with knee joint pain and two with shoulder joint pain, corresponding to the same joint that was injected during the MR arthrogram procedure (the case-patient with bilateral shoulder MR arthrograms had only one joint infected). No commonalities in the case-patients were found other than receiving an MR arthrogram at Facility A. All five confirmed case-patients were hospitalized at different medical centers for further



management and were diagnosed with septic arthritis. Bacterial cultures of synovial fluid for all five confirmed case-patients grew methicillin-sensitive *Staphylococcus aureus* (MSSA) with the same antibiotic sensitivity profile. The two possible case-patients were seen and evaluated in EDs and diagnosed with joint effusion and/or inflammatory reaction and were not hospitalized; one of these two case-patients received oral antibiotics on initial evaluation; synovial fluid gram stain and culture were negative for both of these patients. For the seven case-patients, average onset time of new acute joint pain symptoms following the MR arthrogram procedure was 1.1 days (range 1-2 days) and the average time to hospitalization or ED visit following the MR arthrogram procedure was 4.6 days (range 1-9 days). Average length of hospitalization for the five confirmed case-patients was 10.8 days (range 5-16 days). All five confirmed case-patients required surgical arthroscopic incision and drainage, peripherally inserted catheter placement, and six weeks of intravenous antibiotics for treatment of septic arthritis.

FIGURE



Infection Control/Aseptic Technique Procedure Review

ACDC conducted a site visit and interviewed the chief radiologist and the RT staff regarding infection control procedures and the MR arthrogram procedure, including injectable medication and contrast media preparation.

ACDC learned that intra-articular injectable medication and contrast media preparation is performed at Facility A by either of two radiologic technologists in one fluoroscopy room, which contains a sink. The chief radiologist is the only radiologist who performs MR arthrograms at this facility. ACDC was informed that the following pharmaceuticals were used for MR arthrogram procedures: (1) lidocaine from a 10 mL ampule is used for local anesthesia, 5 mL per patient, (2) approximately 5-10 mL of Optiray® 350 (iversol) is injected intra-articularly for either knee or shoulder MR arthrograms, (3) 10 mL of a 1:200 dilution of Magnevist® (gadopentetate dimeglumine) is injected intra-articularly for either knee or shoulder MR arthrograms, and (4) 10 mL of 0.9% sodium chloride solution (saline) from 10 mL single-dose vials is used to dilute the Magnevist®. The following infection control and pharmaceutical preparation issues were noted:



1. No written office procedures or policies for infection control were in place and there were no specific written procedures for injectable medication and contrast media preparation using aseptic technique.
2. There was no documentation of lot numbers of injectable medications and contrast media solutions (Optiray®, lidocaine, saline, Magnevist®) used for patients.
3. There was no documentation of the exact dosages of Optiray® and lidocaine used on each patient.
4. Open dates were not written on unsealed medication and contrast media vials.
5. Lidocaine syringes were prepared in advance for some patients and left on the procedure tray but were not labeled with either the medication contained or the date and time of preparation.

ACDC conducted a second site visit specifically to observe injectable medication and contrast media preparation procedures. ACDC was informed that it is routine procedure at Facility A for two RTs to each prepare medications and contrast media for the MR arthrogram procedure. There were no duty statements for the RTs. There were no documented staff trainings or competency evaluations for staff on infection control practices or use of aseptic technique.

The injectable medication and contrast media preparation process involved both RTs. ACDC was informed that one RT was to maintain aseptic, sterile technique and the other RT provided assistance in performing non-sterile functions. The RTs were told by ACDC to prepare medications and contrast media in their usual fashion, so ACDC could observe both RTs performing each of their individual roles. ACDC observed multiple infection control deficiencies including breaches in aseptic technique when preparing contrast media (Magnevist® and Optiray®), and use of single-dose vials of the contrast media incorrectly as multi-dose vials for multiple patients. There were no written procedures for medication or contrast media preparation using aseptic technique.

Retrospective Cohort Review and Active Surveillance

To ascertain any other cases, ACDC attempted to contact all patients who had received MR arthrograms two months prior to the one week period. In addition, ACDC conducted active surveillance for all patients who had subsequently received MR arthrograms for one month after the one week period by telephoning these patients and querying if they developed new acute joint symptoms following their MR arthrogram that required further medical evaluation or hospitalization. During the three month study period there were 145 patients who received MR arthrograms at Facility A. Of these, 117 (81%) patients and/or their orthopedic surgeons were successfully contacted. Twenty-eight (19%) could not be contacted (there was no response to messages left with patient or orthopedic surgeon). No other case-patients were identified other than the seven case-patients identified above (five confirmed, two possible).

Microbiologic testing

ACDC was informed by the chief radiologist that Facility A had independently submitted one vial of Optiray® and one vial of Magnevist® previously to a private laboratory. A copy of those results showed no organisms on gram stain and no bacterial growth on culture for both vials that were submitted.

During the second site visit, ACDC obtained one open vial of Optiray® 350 and one open vial of Magnevist® (open dates illegible) from Facility A for testing at the Public Health Laboratory. Both vials were negative for growth of *S. aureus* on bacterial culture.

Synovial fluid culture isolates from the five confirmed case-patients had been discarded prior to ACDC notification of the outbreak and were not available for further molecular epidemiologic analysis by the Public Health laboratory.

Notifications to federal and state agencies



The manufacturer of both Optiray® and Magnevist® were contacted and a MedWatch report was made by the manufacturer of Magnevist® to the Food and Drug Administration (FDA) regarding the five confirmed case-patients of MSSA joint infections following MR arthrograms performed at Facility A. It was noted that single-dose vials of both contrast media were being used incorrectly as multi-dose vials on multiple patients. It was also noted that other solutions in addition to the contrast media were administered (e.g., lidocaine ampule, saline single-dose vial) to the patients.

The CDPH was notified of the outbreak. A report was also made to the CDC's Epidemic Information Exchange (Epi-X). The CDC and the CDPH were consulted. No other case-patients were identified locally or nationally.

CONCLUSIONS AND FINAL RECOMMENDATIONS

Septic arthritis following arthrography is rare. One study in the medical literature reported that only three cases of septic arthritis (0.0024%) were found in 126,000 arthrographic procedures performed¹. In another report, there were no infections associated with approximately 13,300 MR arthrograms performed². In a recent prospective evaluation of 1085 patients who had MR arthrography, no patients had infection³.

In this outbreak investigation, ACDC identified that five of 15 patients (33%) developed septic arthritis during a five-day period following receipt of an MR arthrogram procedure at a single outpatient radiology center and seven of 15 (47%) required hospitalization or emergency department evaluation following the procedure. All case-patients were epidemiologically linked in place and time.

ACDC concludes that this outbreak was more likely than not caused by a breakdown in infection control practices and/or aseptic technique during intra-articular contrast media preparation that could have provided the opportunity for extrinsic contamination of a single contrast media vial resulting in joint infections when injected intra-articularly. This is supported by the findings that: (1) the investigation demonstrated multiple breaches in infection control practices and aseptic technique during contrast media preparation where extrinsic contamination of a contrast media vial could have occurred, (2) single-dose contrast media vials were being used incorrectly as multi-dose vials on multiple patients, (3) during the five-day period in which the outbreak occurred, the use of ~1 mL or ~10 mL of either contrast media used per patient, Magnevist® or Optiray® respectively, is consistent with the use of a single 10 mL vial of Magnevist® or a single 100 mL vial of Optiray®, either of which would have been used on a maximum of ten patients, and (4) the case-patients were clustered temporally and no other case-patients were identified; the extent of the outbreak was limited, making a localized point source most likely. If the infections were due to a contaminated vial, depending on the amount of contamination to which these patients were exposed, patients would be affected with joint infection, joint inflammation or effusion, or may not have been affected during this five day-period. It is considered unlikely that the lidocaine or the saline was responsible for the outbreak particularly because (1) each 10 mL ampule of lidocaine was being used on one or two patients maximum and then the ampule container was discarded and (2) the entire contents of the 10mL vial of saline was being used correctly as a single-dose vial, 10 mL per patient, and then discarded.

Because of lack of documentation on the open date of vials, lack of documentation on which patient received which vials, and because the exact vials that were administered to the case-patients were not available for further testing, it is not possible to determine the exact circumstances which lead to the outbreak of joint infections at Facility A. However, outbreaks of *S. aureus* joint infections due to breakdown in aseptic technique or non-adherence to manufacturer's instructions when using medication vials have been documented in the medical literature^{4, 5}. Because there was lack of documentation as to

¹ Newberg AH, Munn CS, Robbins AH. Complications of Arthrography. *Radiology* 1985; 155: 605-606.

² Hugo PC, Newberg AH, Newman JS, Wetzner SM. Complications of Arthrography. *Semin Musculoskelet Radiol* 1998; 2: 345-348.

³ Saupé N, Zanetti M, Pfirrmann CW, et al. Pain and other side effects after MR arthrography: prospective evaluation in 1085 patients. *Radiology* 2009 Mar;250(3):830-8.

⁴ Kirschke DL, Jones TF, Stratton CW, et al. Outbreak of Joint and Soft-Tissue Infections Associated with Injections from Multidose Medication Vial. *Clin Infect Dis* 2003; 36: 1369-73.

⁵ Murray RJ, Pearson JC, Coombs GW, et al. Outbreak of Invasive Methicillin-Resistant *Staphylococcus aureus* Infection Associated with Acupuncture and Joint Infection. *Infect Control Hosp Epidemiol* 2008; 29: 859-65.



which patients received which contrast media vials, it is impossible to know if the vials that Facility A sent for testing were the vials used on the five confirmed case-patients during the one week outbreak period. Consultations with the CDC and CDPH indicated that breaks in infection control and/or aseptic technique are likely contributors to this outbreak. Although it is theoretically possible that an unidentified environmental source or breach in MR arthrogram injection technique was responsible for the outbreak, ACDC considers this unlikely as no other case-patients were identified other than during the one week outbreak period, supporting the conclusion that a breach in infection control or aseptic technique most likely occurred during that time period and suggests that no persistent source was present.

Review of the medical literature revealed few studies looking at the risks of re-using single-dose contrast media vials. Citing the expensive cost of discarding unused portions of single-dose contrast media vials, two small reports in the medical literature have studied re-use of contrast media that is intended only for single-dose use^{6, 7}. However, this practice is not scientifically established nor can it be generalized as a standard of practice and it is against manufacturer's recommendations for single-dose vials^{8, 9}. Single-use (single-dose) vials are not designed for multiple entries for withdrawal of contents and might pose a risk for contamination if they are punctured several times¹⁰. In addition, single-dose vials are frequently preservative-free. When products packaged in single-dose vials are used as multi-dose vials, the probability for contamination is increased. Therefore, products labeled as single-dose containers should be used to supply a dose for a single patient and any residual product should be discarded and not retained for use on other patients. Outbreaks have occurred when single-dose vials of drugs, including contrast solutions, were re-used on multiple patients^{11, 12, 13}. In a study testing antimicrobial properties of magnetic resonance imaging contrast media, all of the four contrast media that were tested (including gadopentetate dimeglumine) did not meet minimum compendia criteria (using official methodology and acceptance criteria from the United States, Great Britain, and Europe) for effectiveness of antimicrobial preservative and this study concluded that their findings do not support multidose use of magnetic resonance contrast media¹⁴.

A recurrence of an outbreak of joint infections at Facility A should be prevented by strict adherence to proper infection control practices, use of aseptic technique when performing MR arthrograms, and following manufacturer's instructions for contrast media use. Facility A was instructed to report any patients with possible joint infections following MR arthrograms to ACDC. ACDC recommended that Facility A keep logs of lot numbers, document dosages, label pre-filled syringes, and write open dates on multidose vials. ACDC emphasized with Facility A to follow strict adherence to the manufacturer's recommendations for single-dose contrast media vial use; that single-dose vials should never be used for more than one patient and any residual product should be discarded and not retained for later use on other patients; develop procedures and follow proper infection control practices; review duties of radiologic technologists and ensure consistency with job duties and scope of practice, including preparing and diluting medications and contrast media for intra-articular injection; and to develop procedures and routine training and competency review for use aseptic technique when preparing injection medications and contrast media.

⁶ Green KA, Mustachi B, Schoer K, et al. Gadolinium-based MR Contrast Media: Potential for Growth of Microbial Contaminants When Single Vials Are Used for Multiple Patients. *Am J Roentgenol* 1995; 165: 669071.

⁷ Kamishima T, Schweitzer ME, Awaya H, Abraham D. Utilization of "Used" Vials: Cost-Effective Technique for MR Arthrography. *J Magn Reson Imaging* 2000; 12: 953-955.

⁸ Magnevist package insert. Wayne, NJ: Bayer Healthcare Pharmaceuticals. 2007 June.
http://berlex.bayerhealthcare.com/html/products/pi/Magnevist_PI.pdf?WT.mc_id=www.berlex.com

⁹ Optiray 350 package insert. Hazelwood, MO: Mallinckrodt Inc. Tyco Healthcare. 2008 March.

<http://www.imaging.mallinckrodt.com/imageServer.aspx/doc133715.pdf?contentID=13542&contenttype=application/pdf>

¹⁰ Centers for Disease Control and Prevention. Guidelines for the prevention of intravascular catheter-related infections. *MMWR Recomm Rep* 2002; 51: 1-29.

¹¹ Cohen AL, Ridpath A, Noble-Wang J, et al. Outbreak of *Serratia marcescens* Bloodstream and Central Nervous System Infections After Interventional Pain Management Procedures. *Clin J Pain* 2008; 24: 374-380.

¹² Pan A, Dolcetti L, Barosi C, et al. An Outbreak of *Serratia marcescens* Bloodstream Infections Associated with Misuse of Drug Vials in a Surgical Ward. *Infect Control Hosp Epidemiol* 2006; 27: 79-82.

¹³ Grohskopf LA, Roth VR, Feikin DR, et al. *Serratia liquifaciens* Bloodstream Infections from Contamination of Epoetin Alfa at a Hemodialysis Center. *NEJM* 2001; 344: 1491-1497.

¹⁴ Beussink DR, Godat JF, Seaton T. Antimicrobial Properties of Magnetic Resonance Imaging Contrast Media. *Am J Health Sys Pharm* 2007; 57: 48-50.