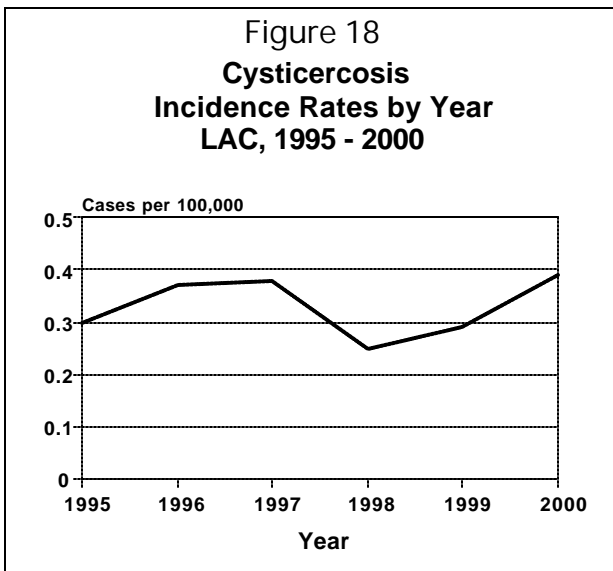


CYSTICERCOSIS

CRUDE DATA	
Number of Cases	32
Annual Incidence ^a	
LA County	0.4
United States	N/A
Age at Onset	
Mean	36
Median	38
Range	14 - 86 years
Case Fatality	
LA County	12.5%
United States	N/A

^a Cases per 100,000 population.



ETIOLOGY

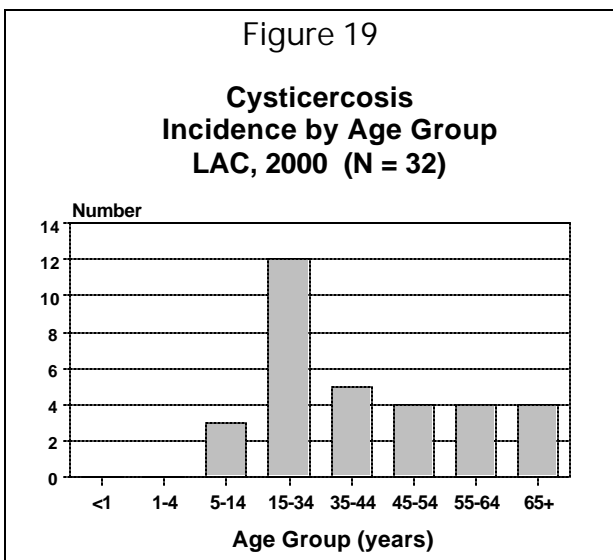
Cysticercosis results from an infection with the larval form of the pork tapeworm *Taenia solium*. It is caused by ingestion of tapeworm eggs excreted in human feces. The larvae that hatch from the eggs are called cysticerci and they may invade any organ. The most serious manifestation is neurocysticercosis, infection in the central nervous system, including the brain, meninges, spinal column, and eye. Tapeworm infection is caused by consuming raw or undercooked meat, usually pork, infested with viable larvae.

DISEASE ABSTRACT

- Most cases occur in persons born in foreign countries where the pork tapeworm is endemic.
- The large majority of LAC cases are born in Mexico and Central America.
- Occasionally cases are acquired locally.

STRATIFIED DATA

Trends: The rate of reported disease has remained stable for the past five years. However, previous studies have demonstrated extensive under-reporting of this disease. Further complicating surveillance is the fact that the disease is lifelong, leading to multiple medical examinations, hospitalizations, and treatments, with the potential for being reported at each occasion.



Seasonality: There is no seasonality to disease onset.

Age: Ages ranged from 14 to 86 years; the greatest number of cases was in persons, aged 15-34 years (Figure 19). Fewer cases occur in children because of the latency between infection and development of clinical symptoms leading to diagnosis. Most acute infections are asymptomatic; symptoms develop months or years later due to the inflammatory response or space-occupying lesions in the central nervous system.

Sex: Of the 32 reported cases, 24 (75%) were male; the male:female rate ratio was 3:1. There is no explanation for the male preponderance.

Race/Ethnicity: Thirty cases (94%) were Hispanic (0.8 cases per 100,000) and 2 (6%) were non-Hispanic White (Figure 20). Twenty-four of the 30 Hispanic cases were foreign born: 20 in Mexico, 3 in El Salvador, and one in Guatemala. Of the 8 cases born in the US, 6 (75%) were Hispanic.

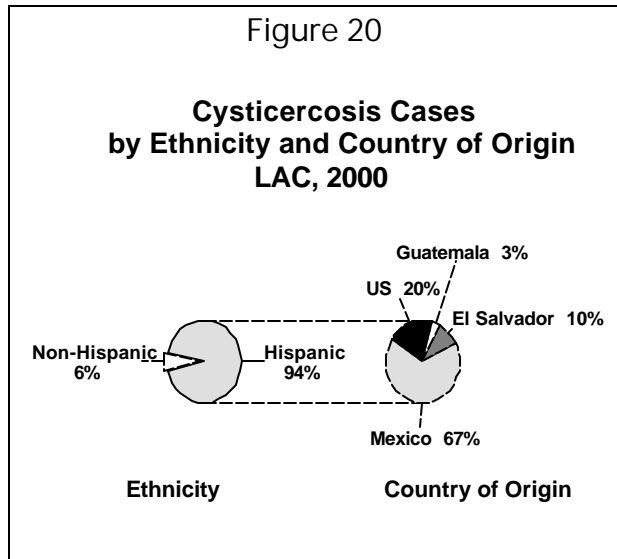
Location: Since the incubation period may be decades long, it is generally not possible to pinpoint the time or place of infection of cases born or traveling frequently outside the US.

Six of the 8 US-born cases gave a history of travel to places endemic for tapeworm, most commonly Mexico (5 cases). Four of those with significant travel histories were aged 18 years or less at diagnosis: one had visited El Salvador in 1998, one made a trip to Mexico in 1996, and 2 cases aged 15 years traveled to Mexico on an annual basis. A 25-year-old man developed seizures three months after a trip to Mexico. The sixth case was 76 years old; his last foreign excursion was to Mexico in 1990. The 2 remaining US-born cases were elderly Hispanic men with no history of foreign travel.

COMMENTS

Symptoms: The most common presenting symptoms were headache (72%) and seizures (63%). In 4 cases diagnosed at autopsy, cysticercosis appeared to be the underlying cause of death, giving a case-fatality rate of 12.5%. One case, a 14-year-old boy, was found dead in bed without preceding symptoms. A 27-year-old man had a history of severe headache for two years; he died suddenly after exacerbation of headache pain. A 49-year-old woman suffered what was presumed to be a massive ischemic stroke; the coroner determined the cause of death as multiple cysticercal lesions in the brain. The fourth fatal case was a 39-year-old man who had been under neurologic care for 10 years before succumbing to the disease. One case had a tumor of the lip that was identified on biopsy as a cysticercus.

Diagnosis: Twenty-seven of 32 cases (84%) were diagnosed by either MRI or CT scan. While such scans are not usually definitive, the diagnosis of cysticercosis can be made with reasonable accuracy given typical appearance, number, and location of brain lesions. Serology may be helpful, especially in individuals without a history of exposure in endemic parts of the world. Serologic tests were significant in all 6 cases where used. Biopsy is the definitive method of diagnosis, and was positive in all 5 cases where used.



Public Health Impact: Stool examinations for ova and parasites (O&P) were performed on only 16 cases (50%): 10 cases submitted three specimens, 4 cases submitted two specimens, and 2 cases submitted only one specimen. Of the 8 US-born cases, 3 were not screened. No tapeworms were identified in this group. Tapeworm carriers are capable of autoinfection, so patients with radiologic evidence of recent (active) cysticercal lesions may carry a tapeworm in their own gut; such patients should submit stool specimens for screening prior to taking the antiparasitic treatment. Treatment with certain antihelminthic drugs successfully eradicates intestinal tapeworm and negates the need to screen the patient further. However, in some circumstances ova and parasite testing may provide information critical to identifying the source of infection.

ADDITIONAL RESOURCES

Cysticercosis Fact Sheet

http://www.cdc.gov/ncidod/dpd/parasites/cysticercosis/factsht_cysticercosis.htm

Controversies in the Management of Cysticercosis

<http://www.cdc.gov/ncidod/eid/vol3no3/evans.htm>

Centers for Disease Control: *Locally acquired neurocysticercosis* – North Carolina, Massachusetts, and South Carolina, 1989-1991. *MMWR* 1992; 41:1-4.

<http://www.cdc.gov/epo/mmwr/preview/mmwrhtml/00015878.htm>

Acute Communicable Disease Control website:

<http://lapublichealth.org/acd/procs/b73/b73index.htm>